# 症例1

- 患者：81才、女性
- 既病歴：平成21年膵尾部癌で手術歴あり。
- 現病歴：平成27年4月にCTにて右肺中葉に
  40×26mmの腫瘤と、両肺野に多発する
  結節影を認め、精査加療目的に入院となった。
  Ex-smoker　10本/日×38-79才
- 検体：TBAC

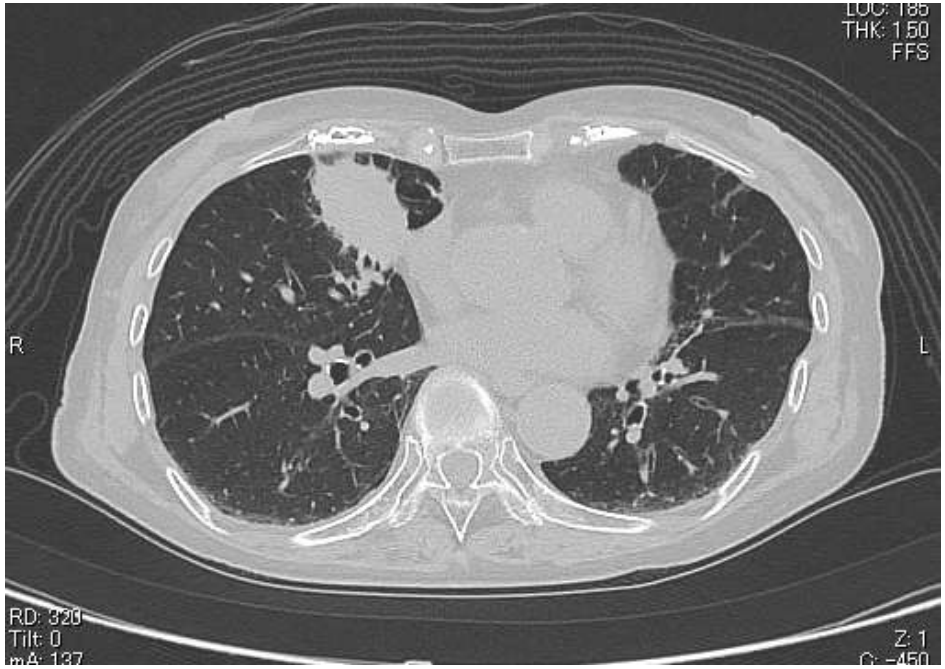
THK: 1.50
FFS
R
L
RD: 320
Tilt: 0
Z: 1

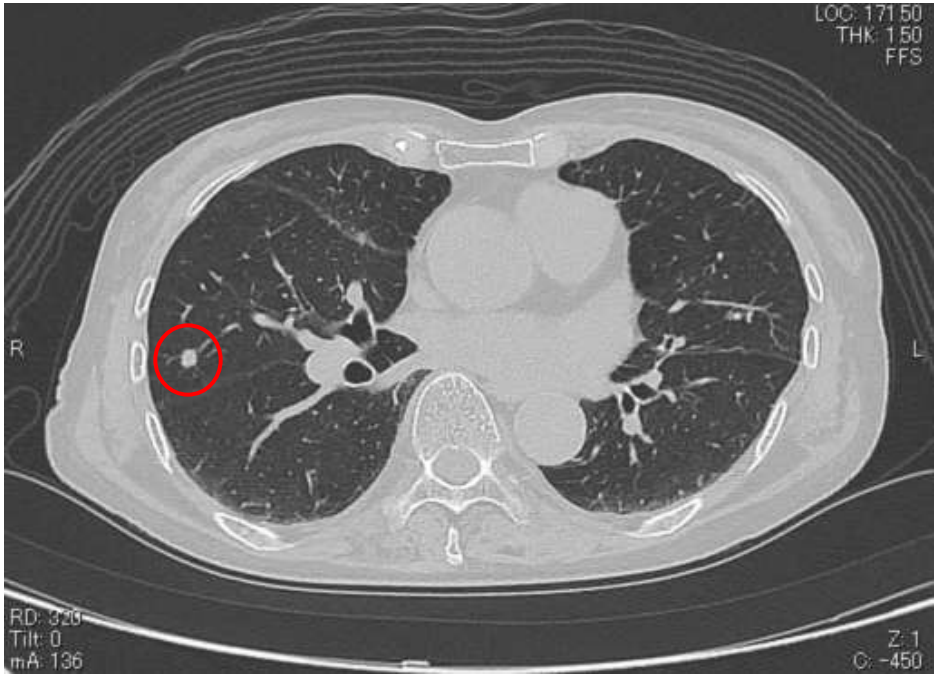
LOC: 171.50
THK: 1.50
FFS
R
L
RD: 320
Tilt: 0
mA: 136
Z: 1
C: -450

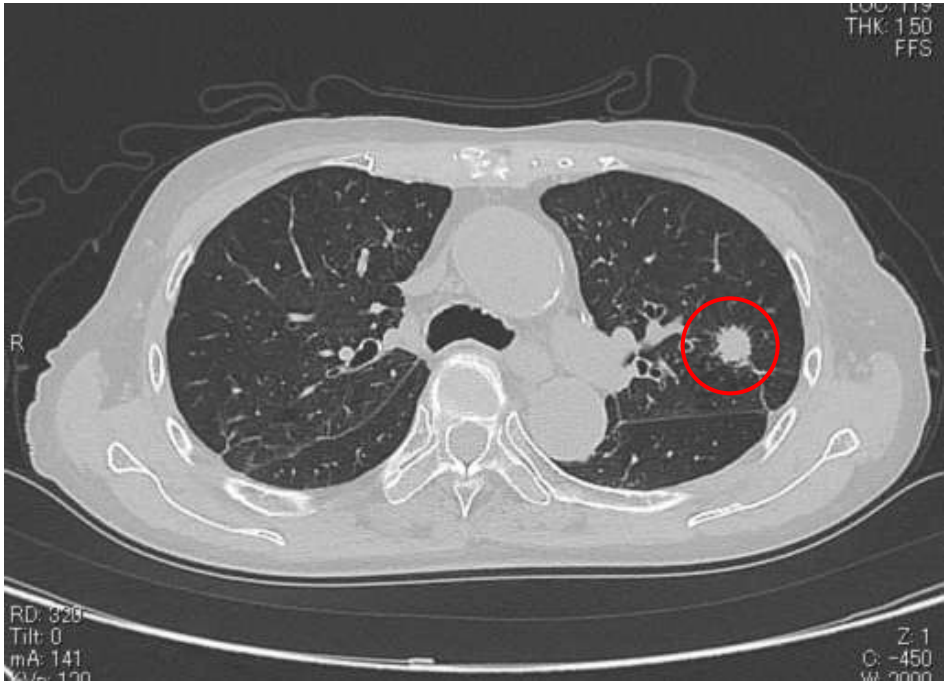
THK: 1.50
FFS
R
RD: 320
Tilt: 0
mA: 141
Z: 1
C: -450

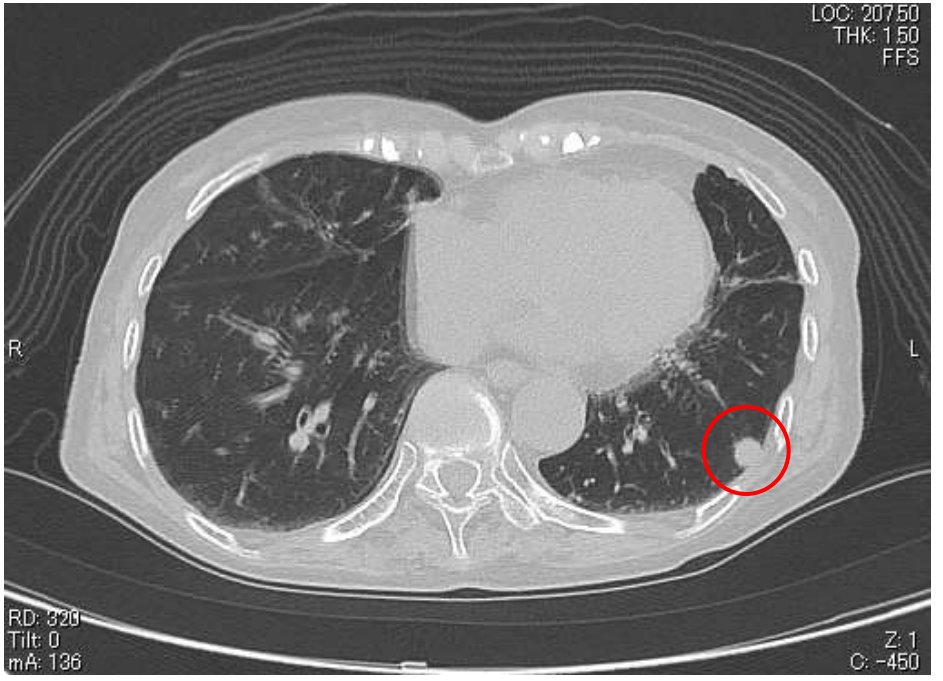
LOC: 207.50
THK: 1.50
FFS
R
L
RD: 320
Tilt: 0
mA: 136
Z: 1
C: -450



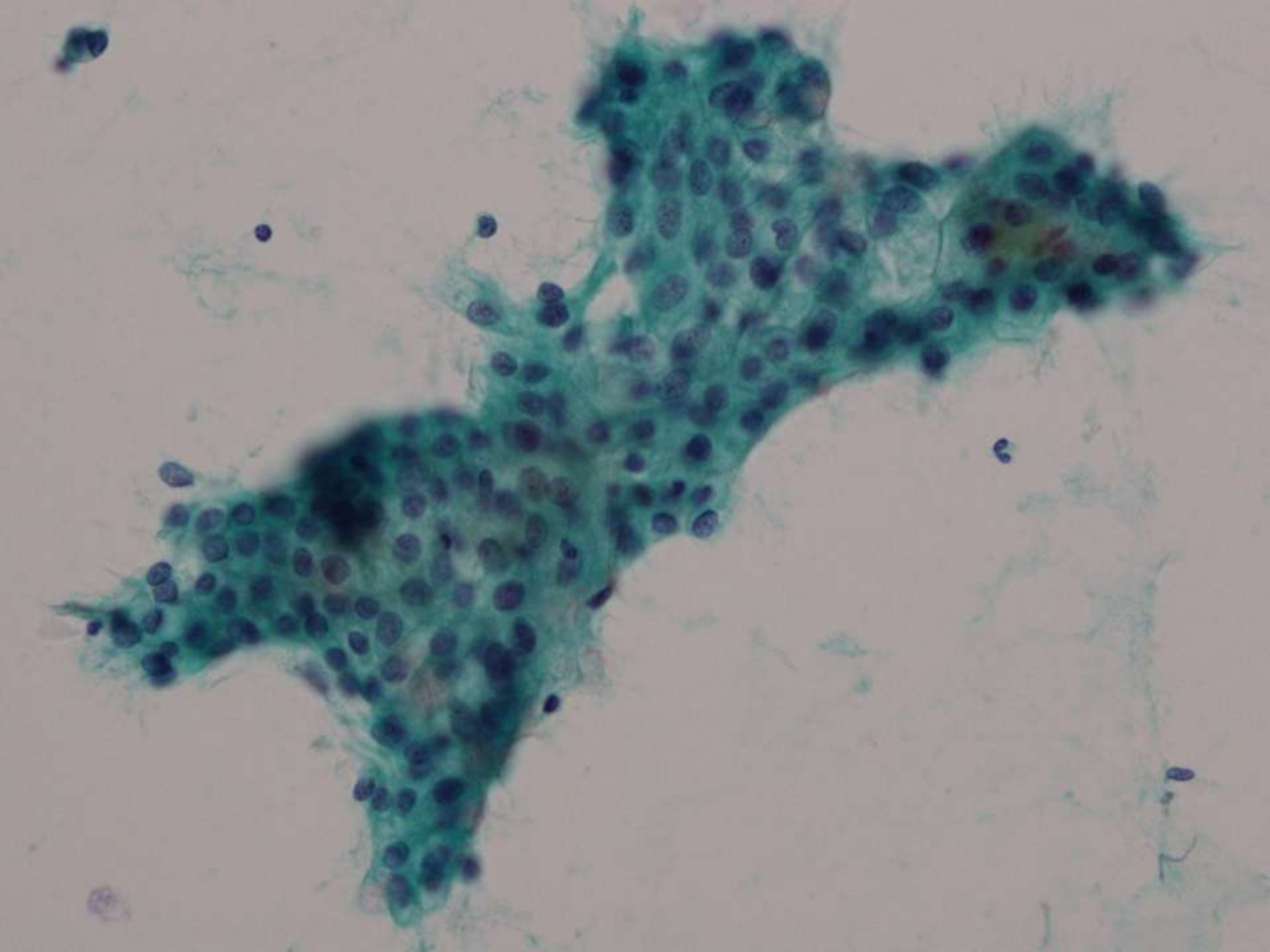

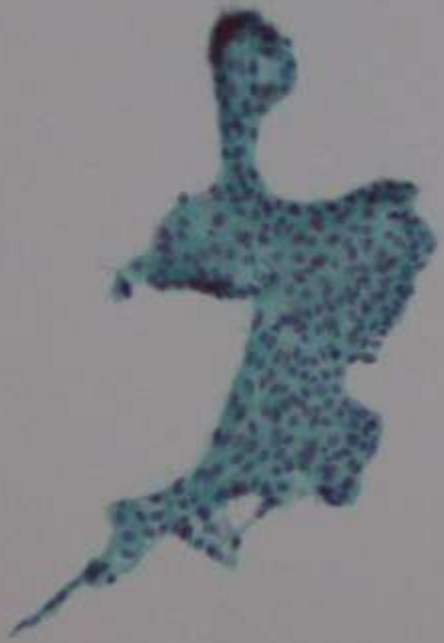

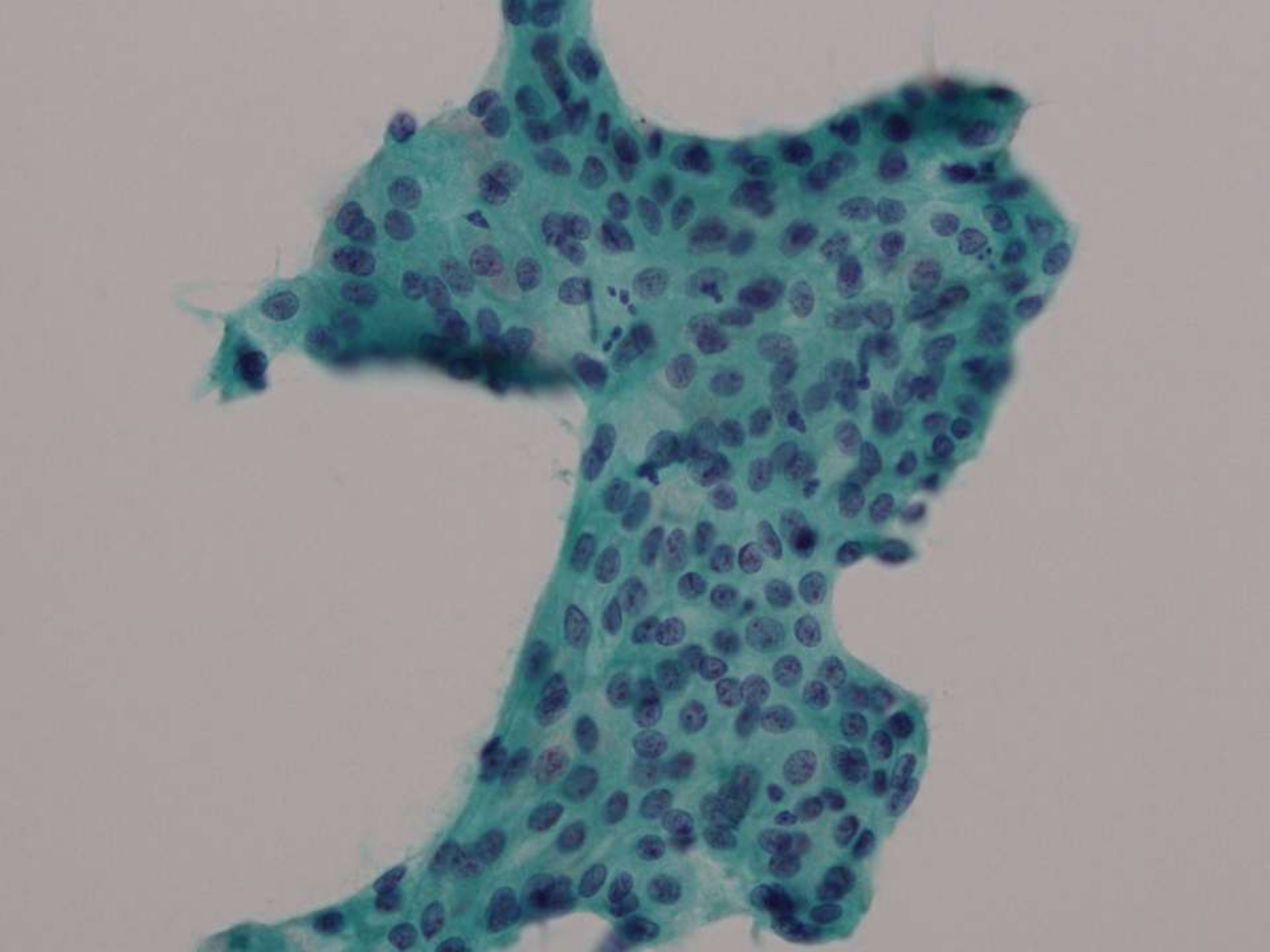

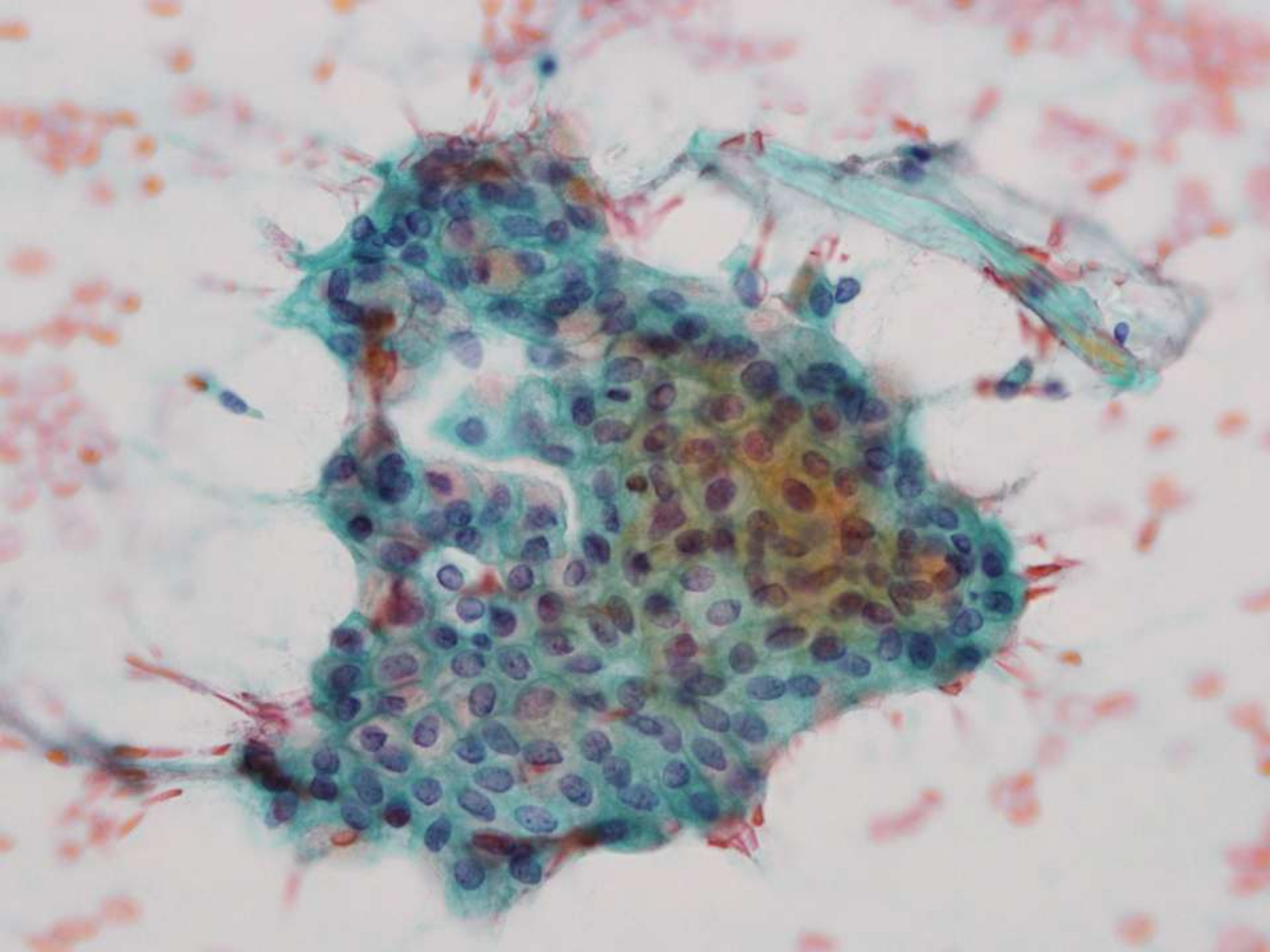

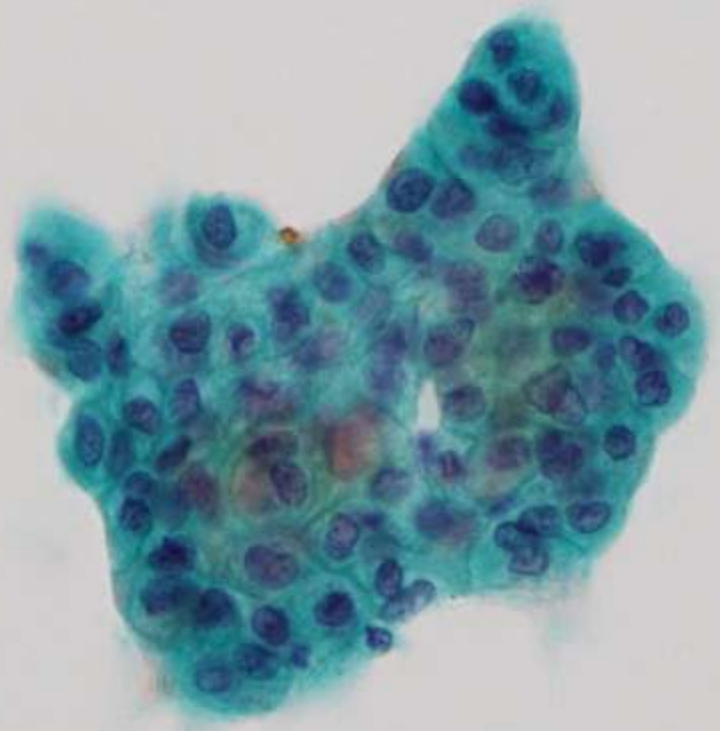

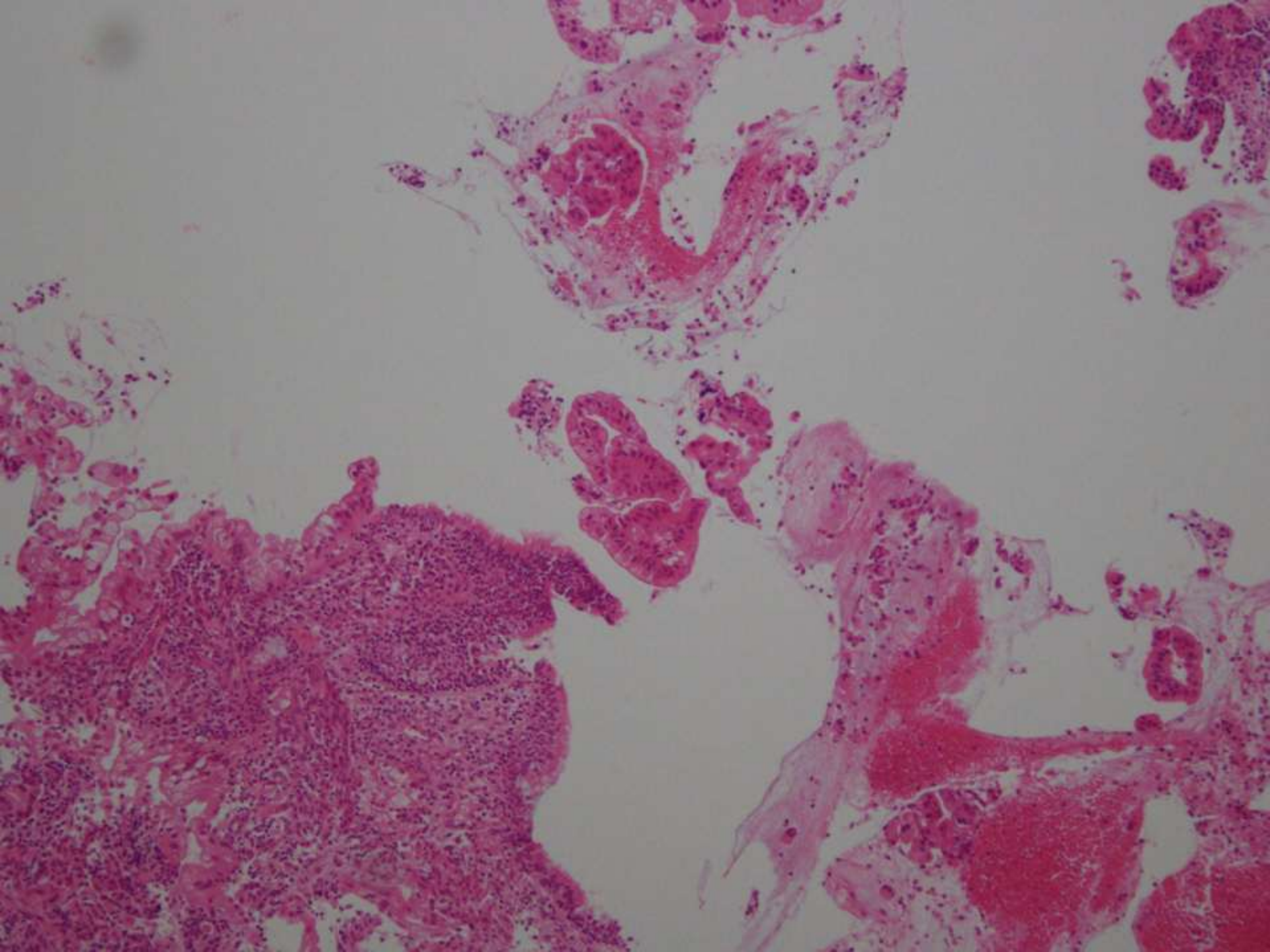

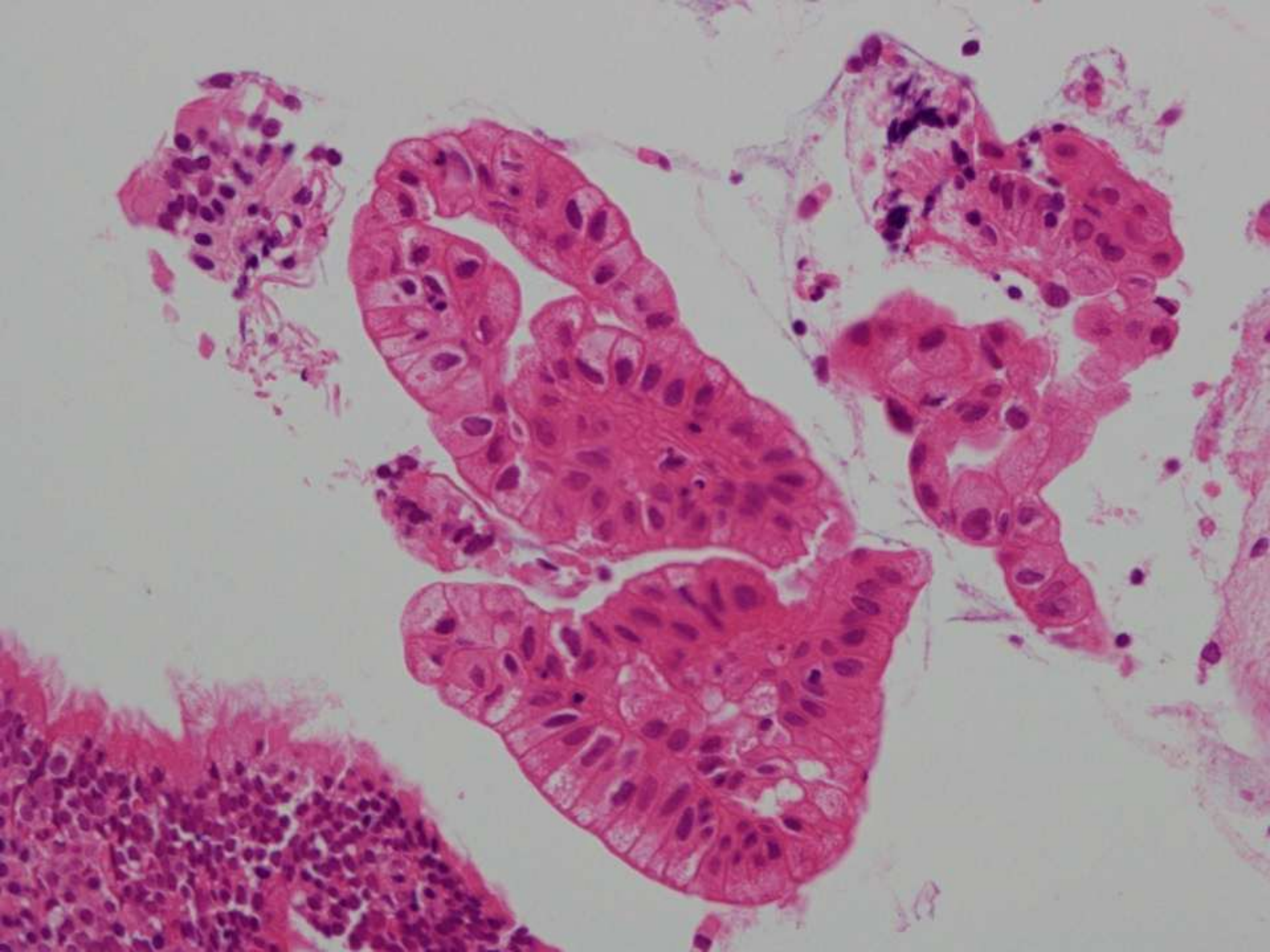

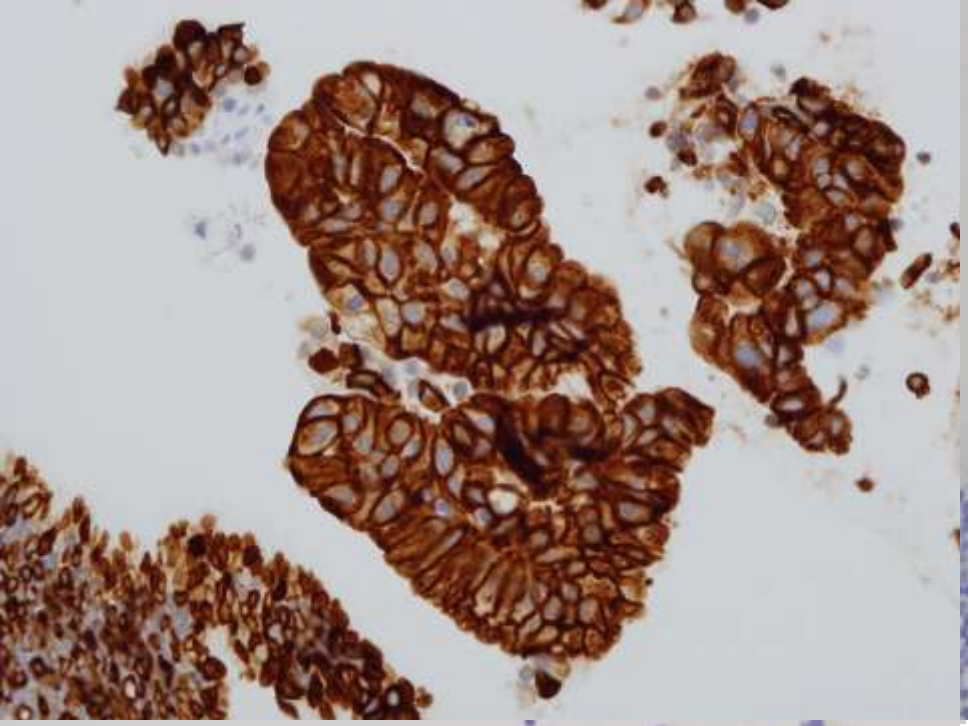

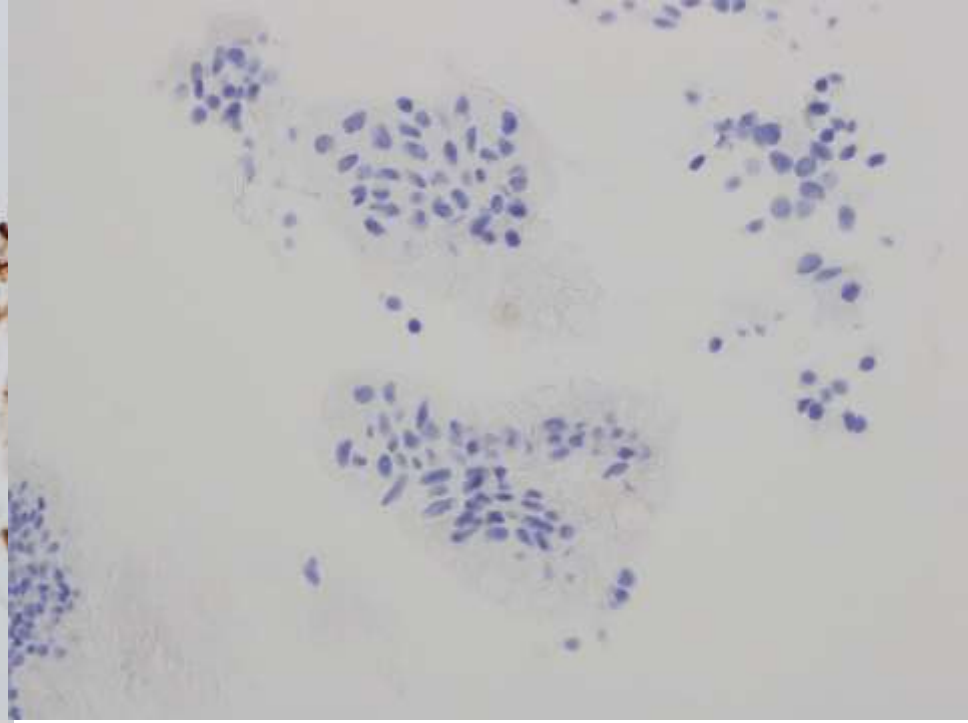

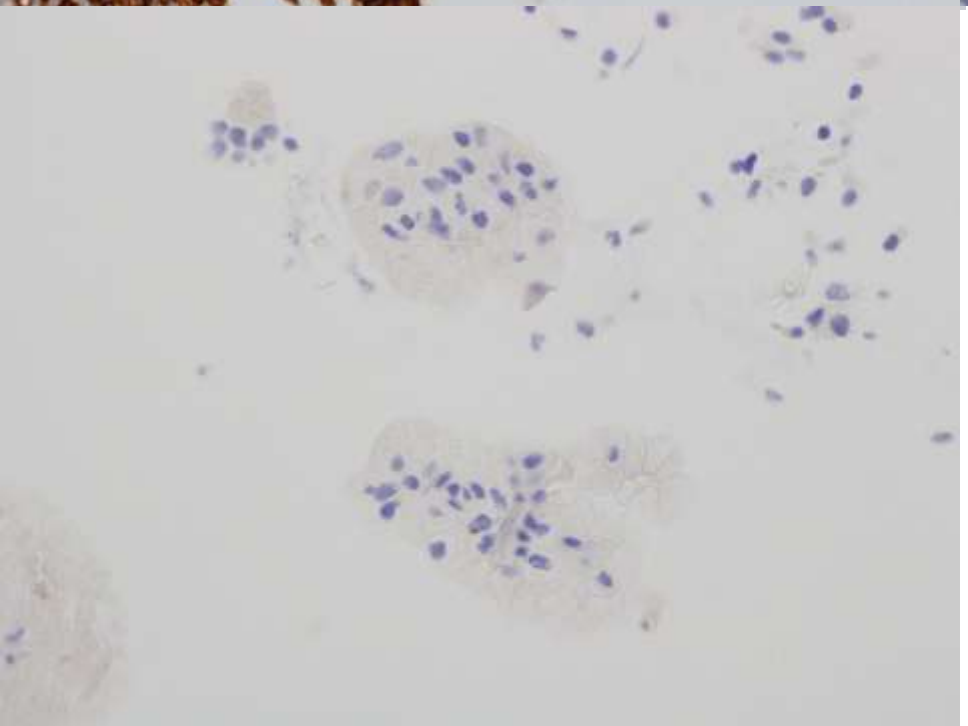

CK7

CK20

TTF-1

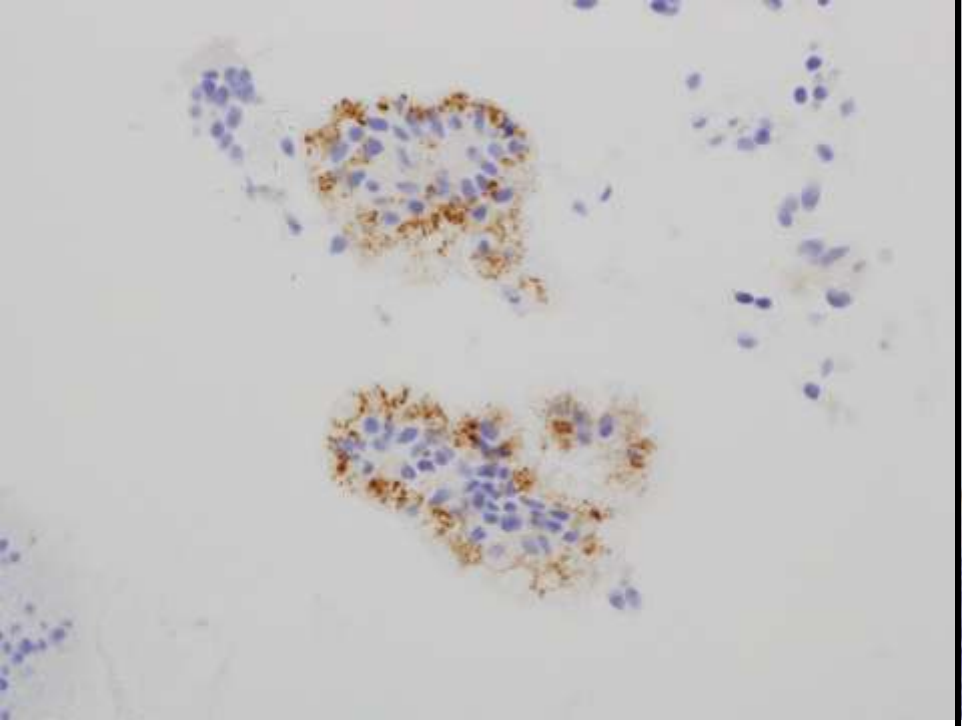

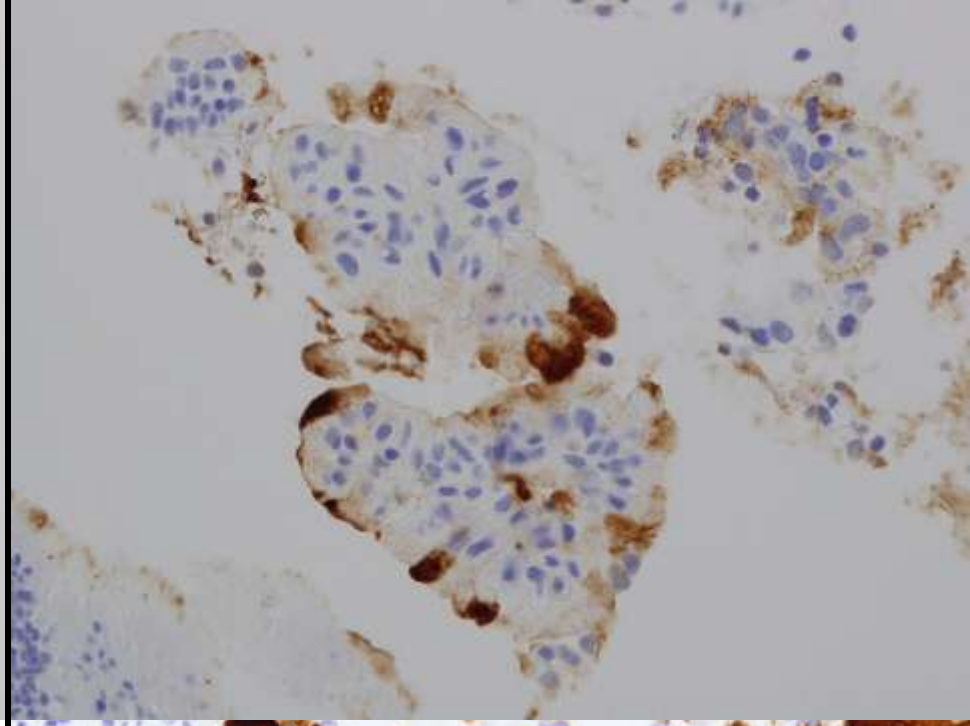

NapsinA | CA19-9

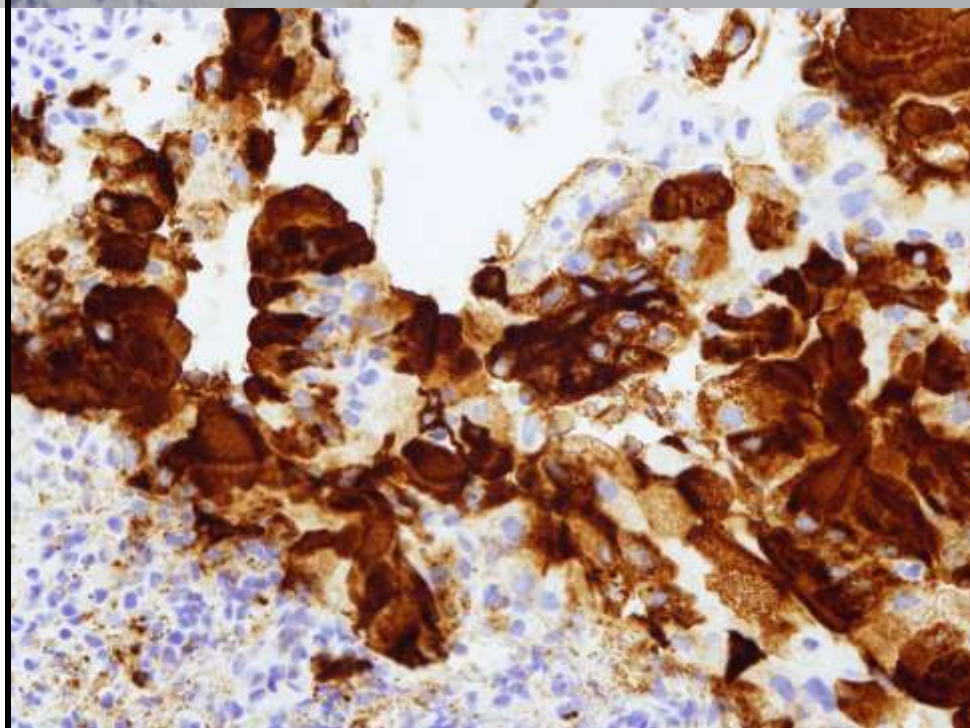

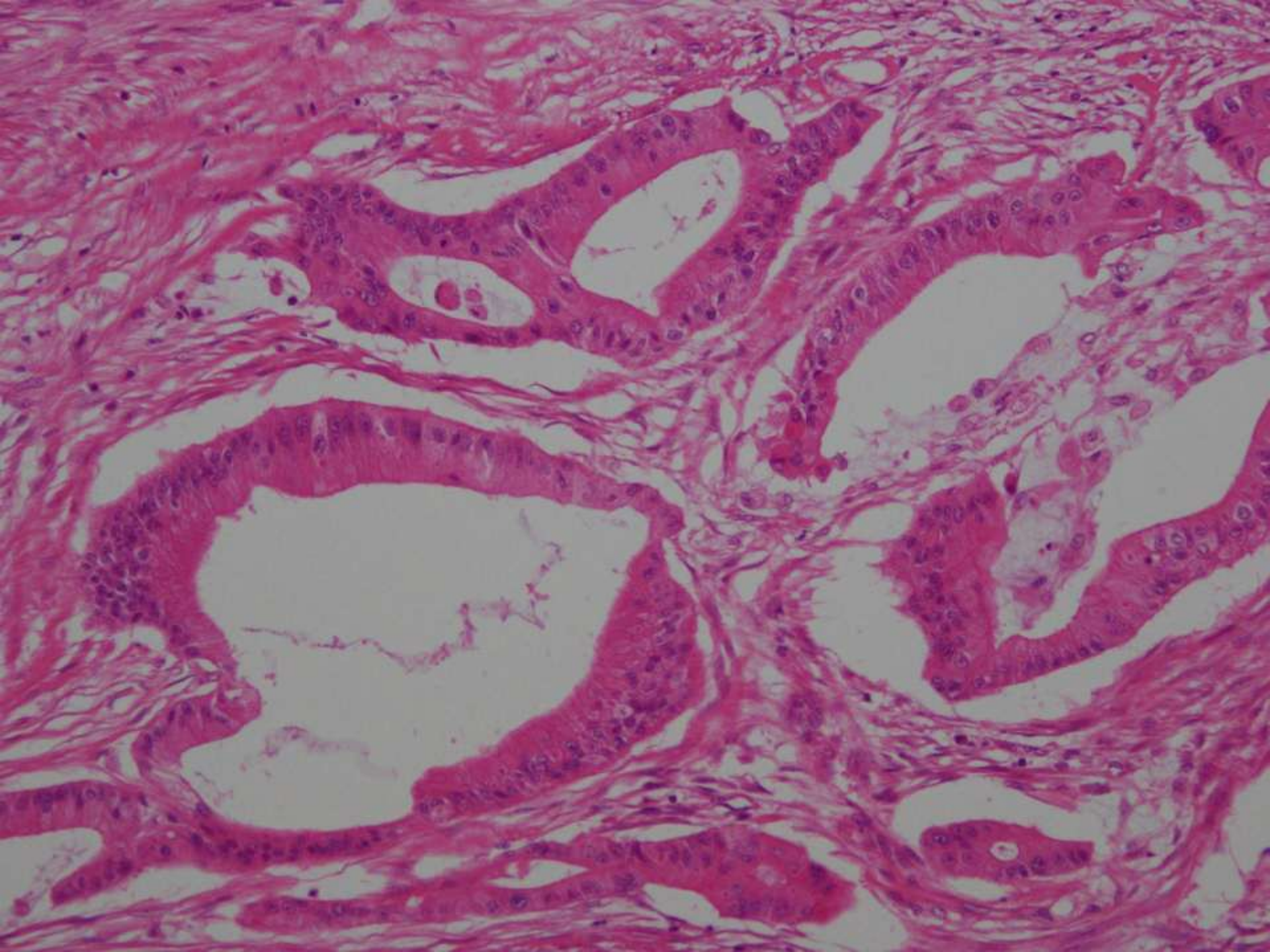

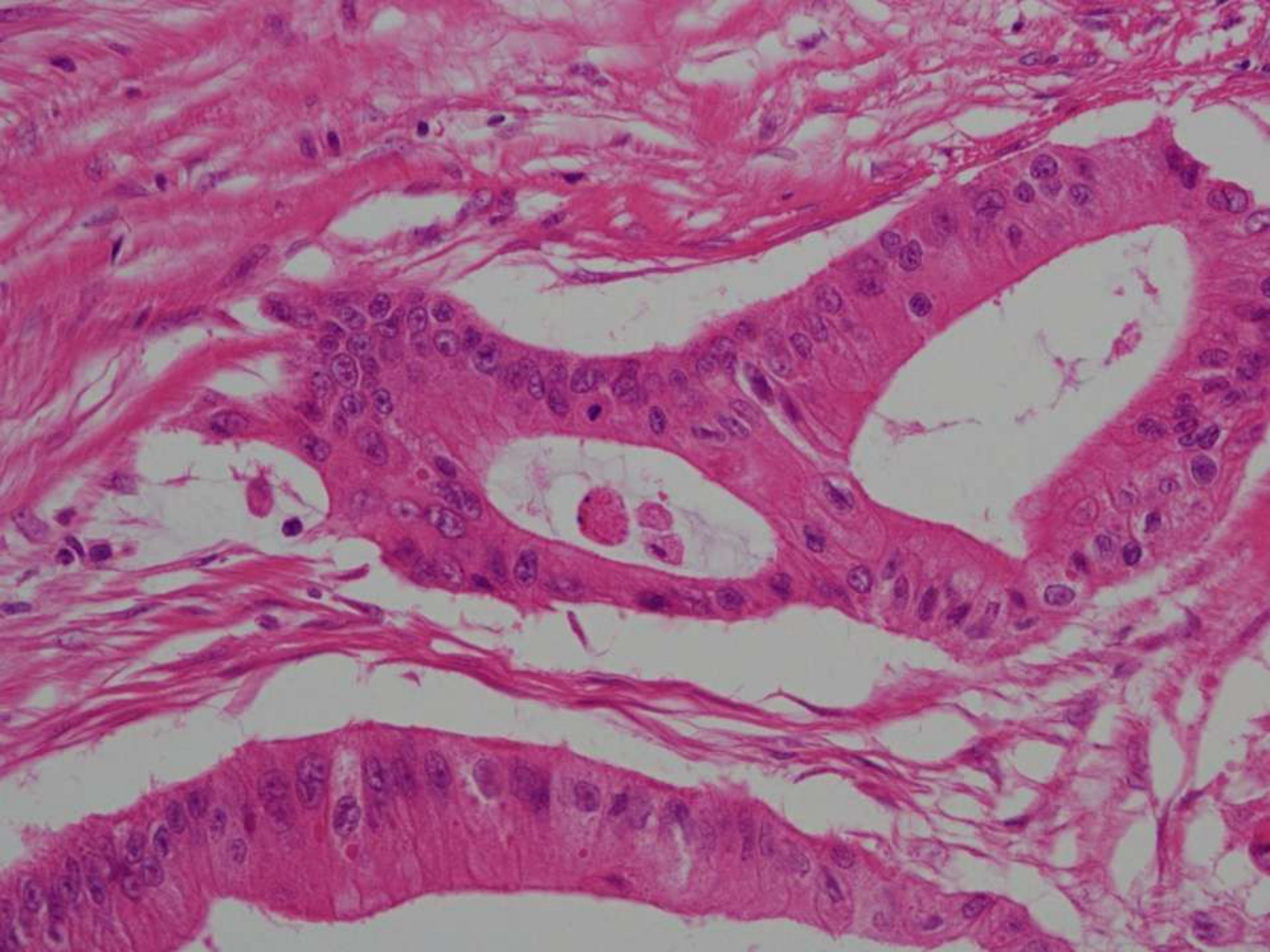

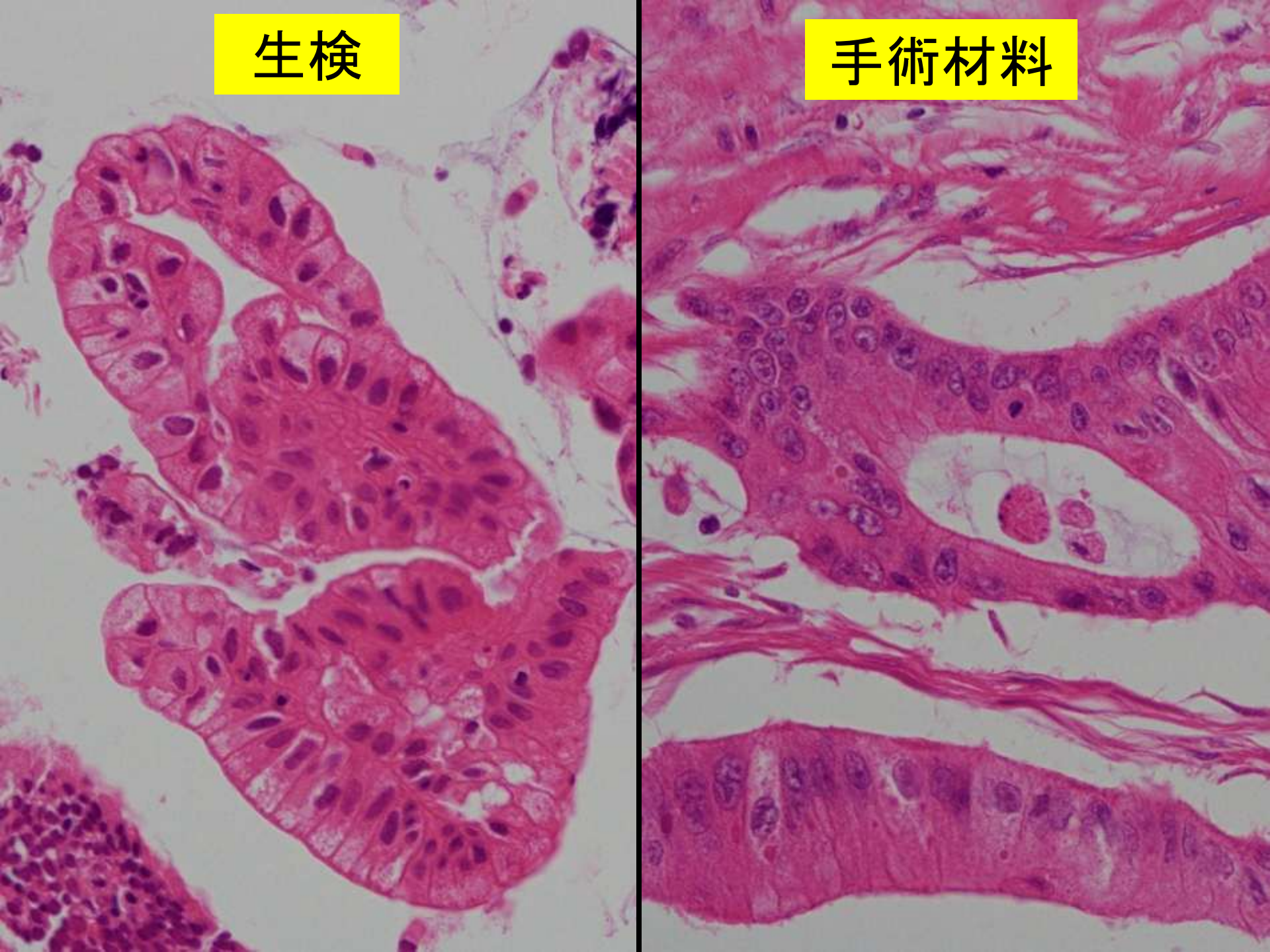
生検
手術材料

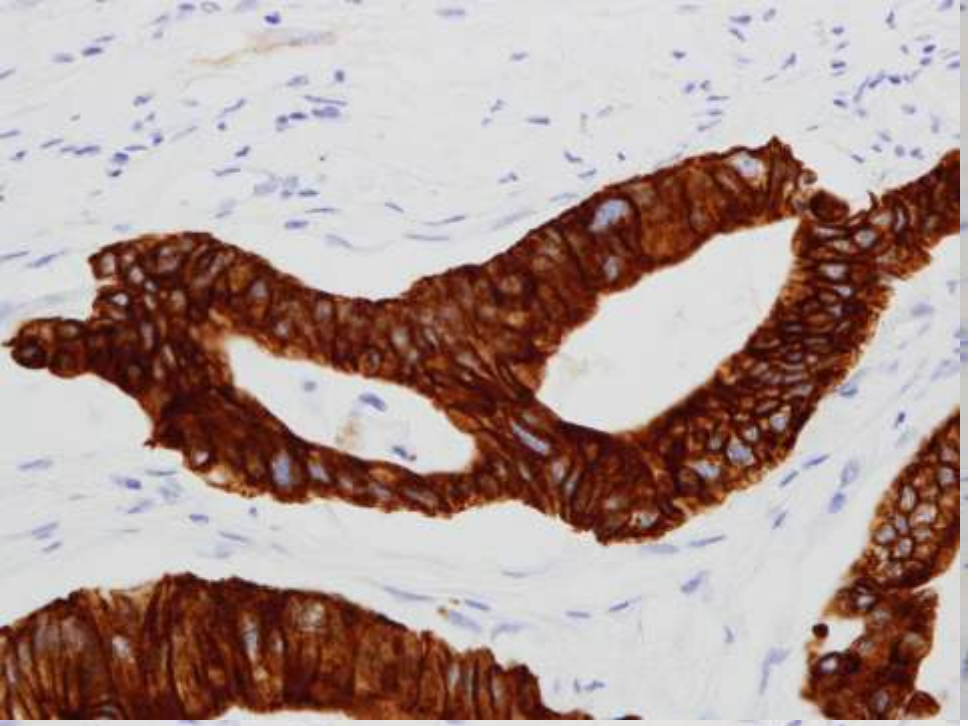

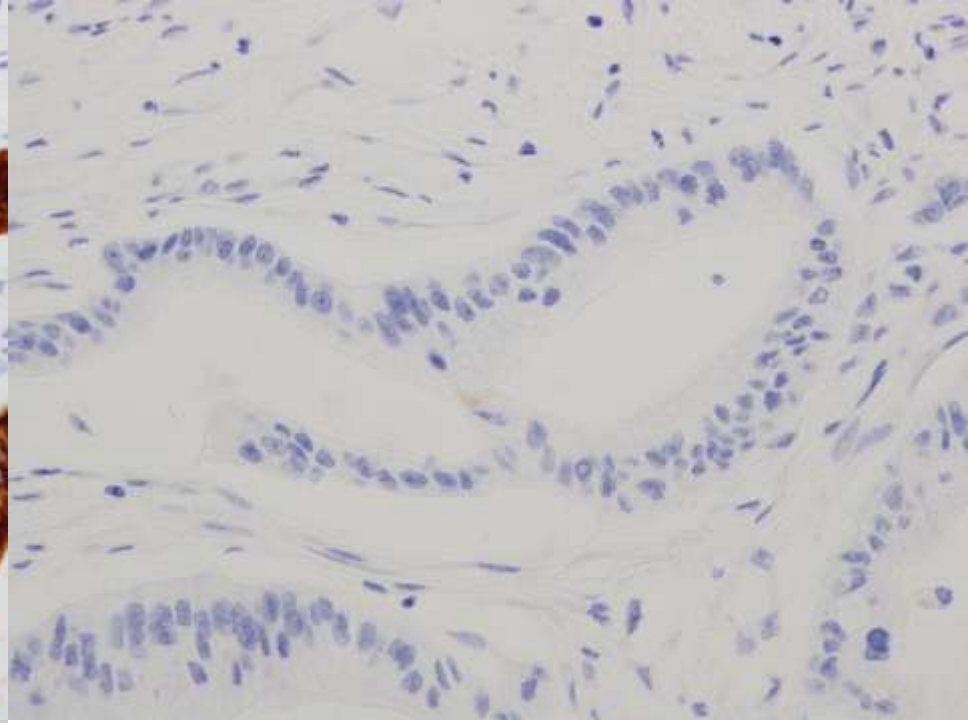

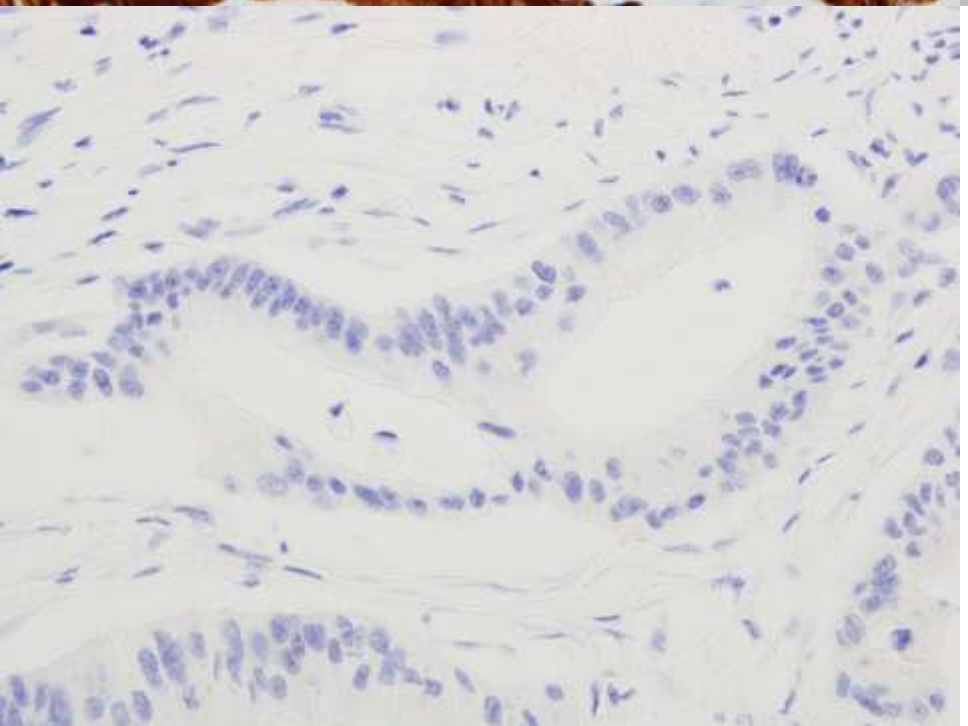

CK7

CK20

TTF-1

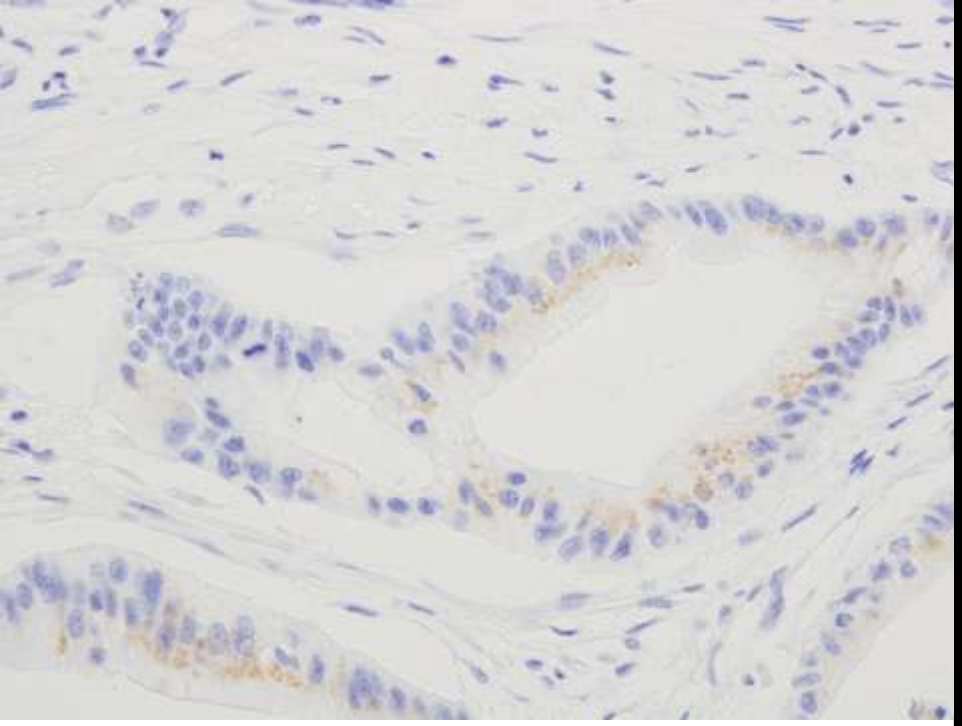

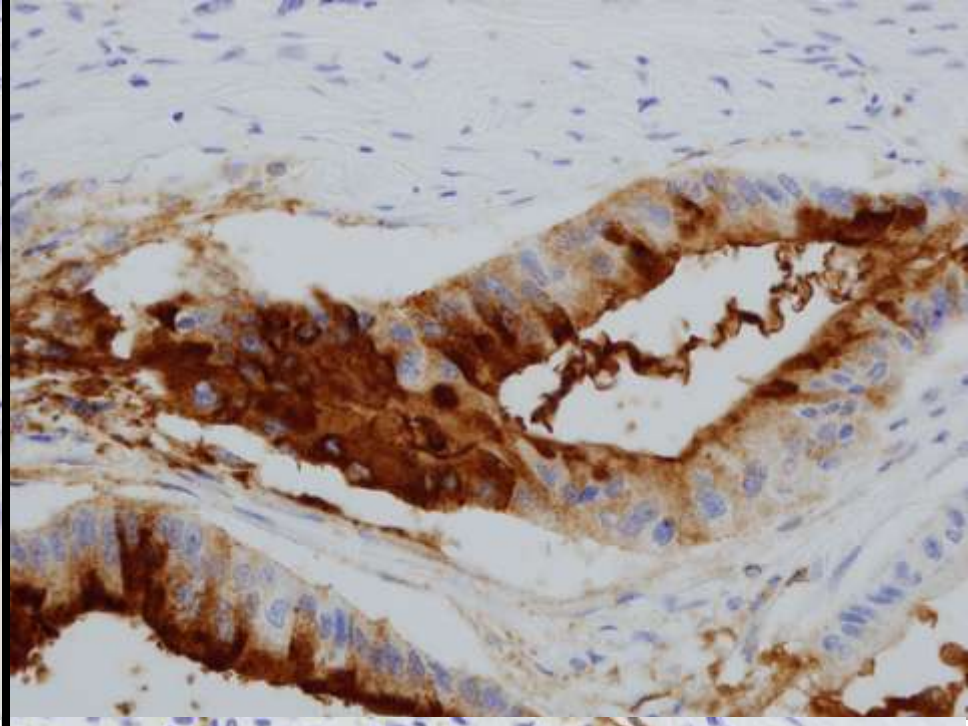

NapsinA

CA19-9

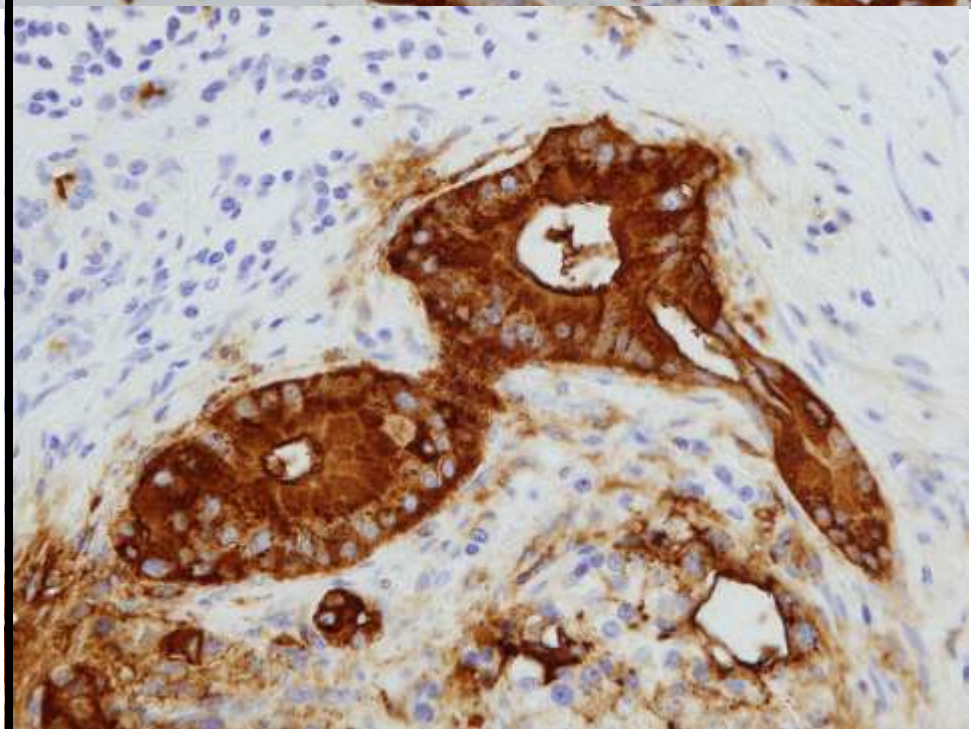

# 最 終 診 断

**Consistent with Metastasis of Pancreatic cancer**

肺生検標本に含まれているAdenocarcinomaは、
既往の膵癌の肺転移として矛盾しません。

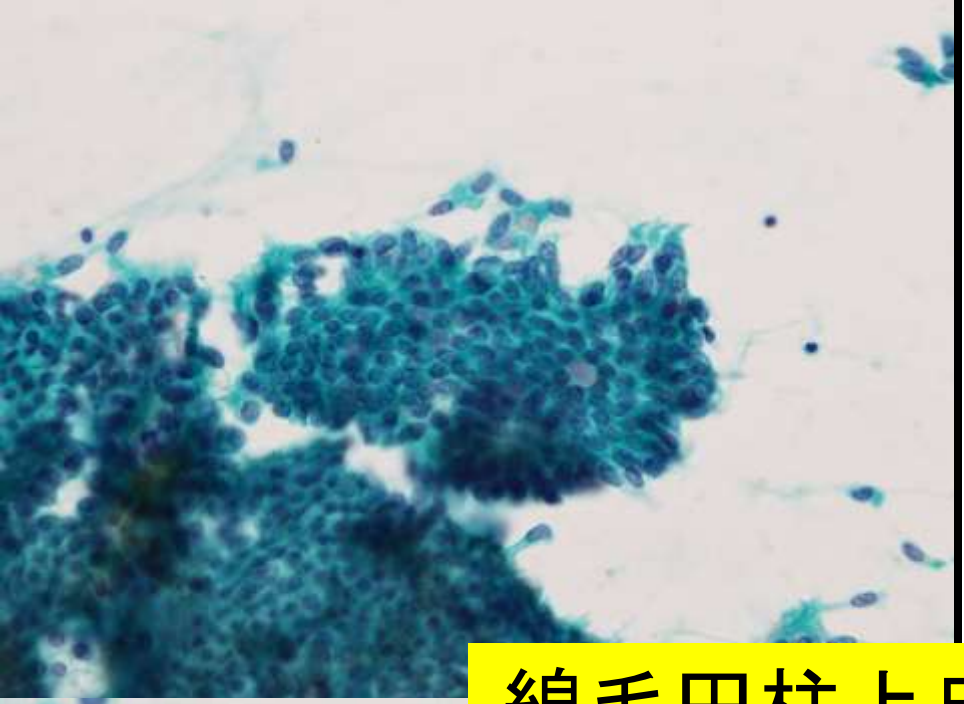

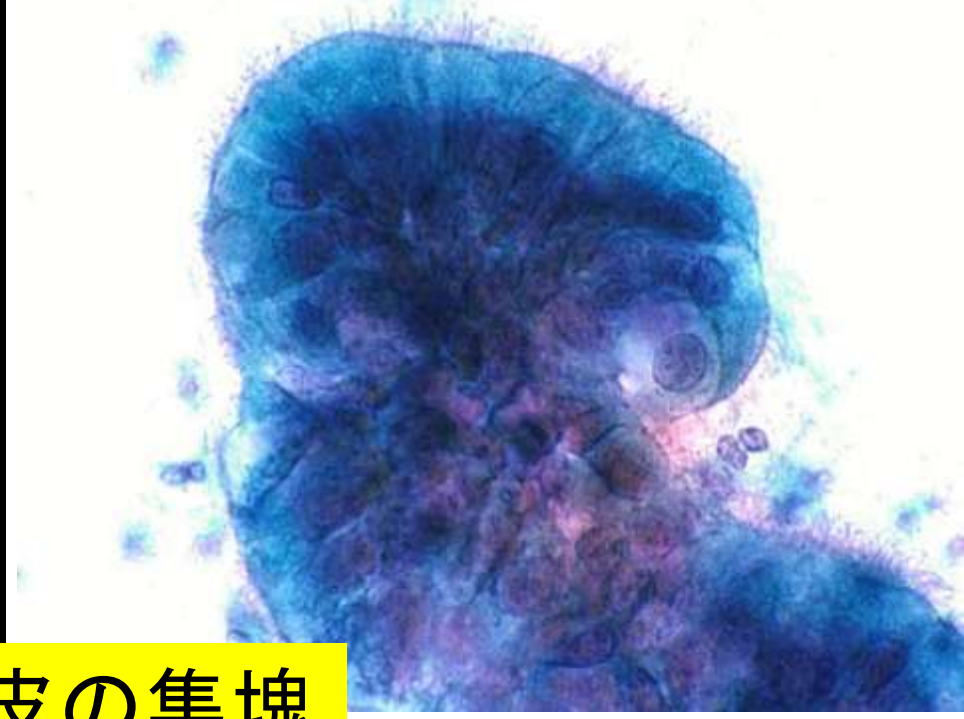

線毛円柱上皮の集塊

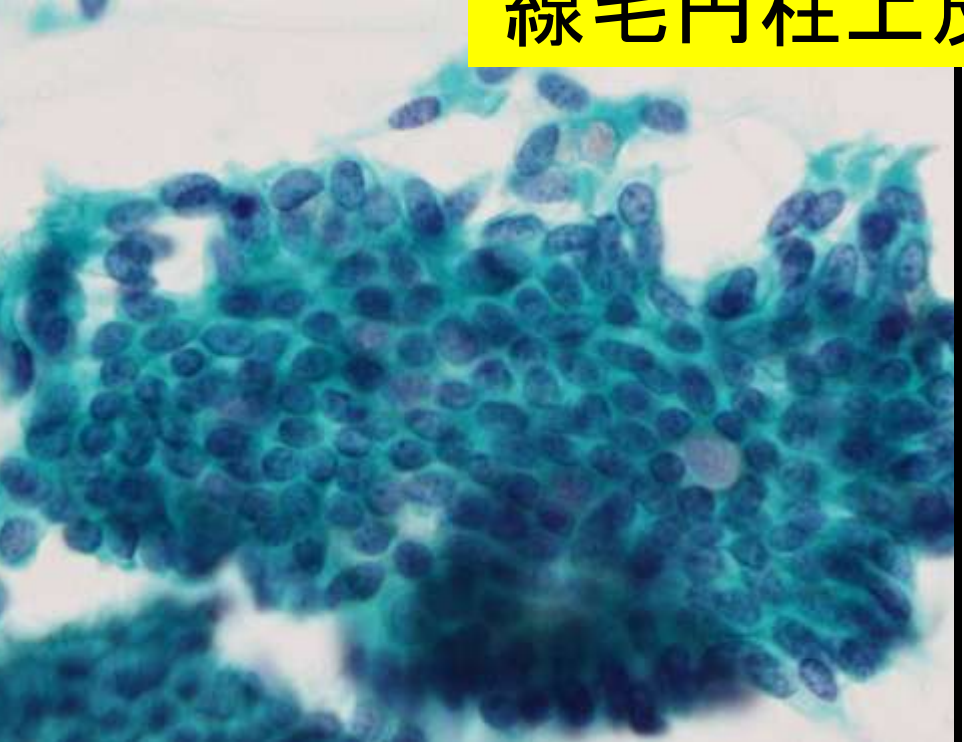

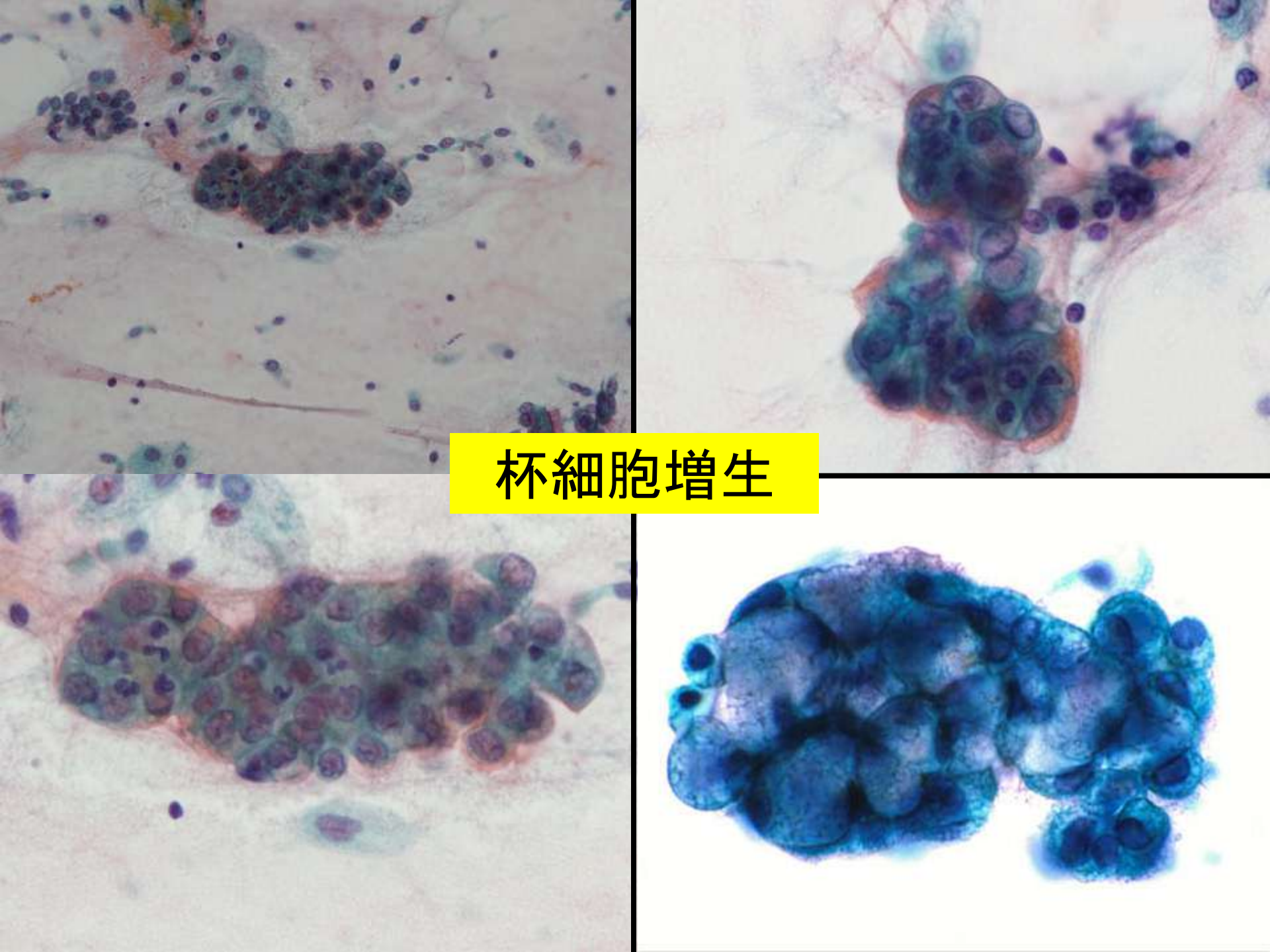
杯細胞増生

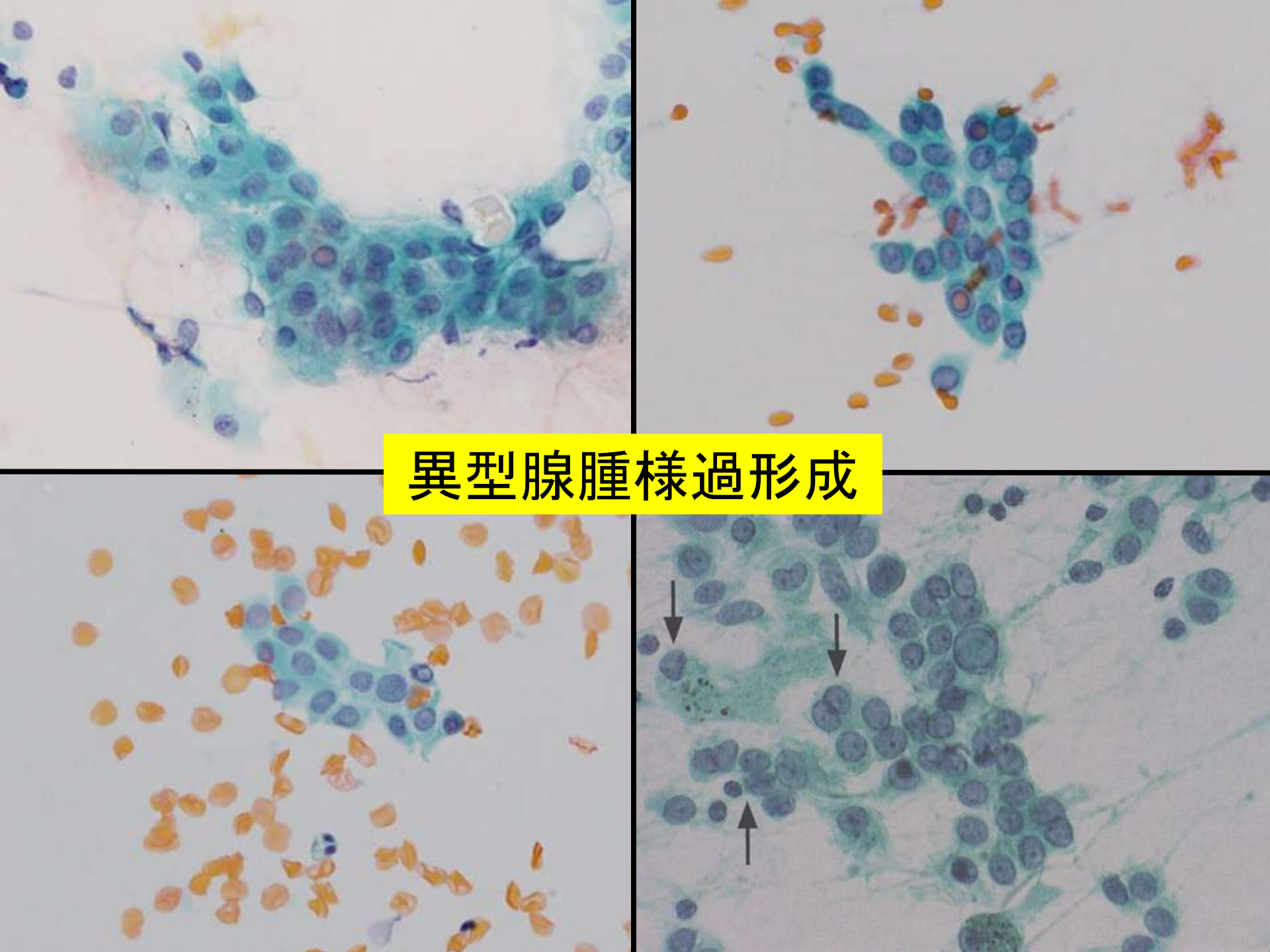
異型腺腫様過形成

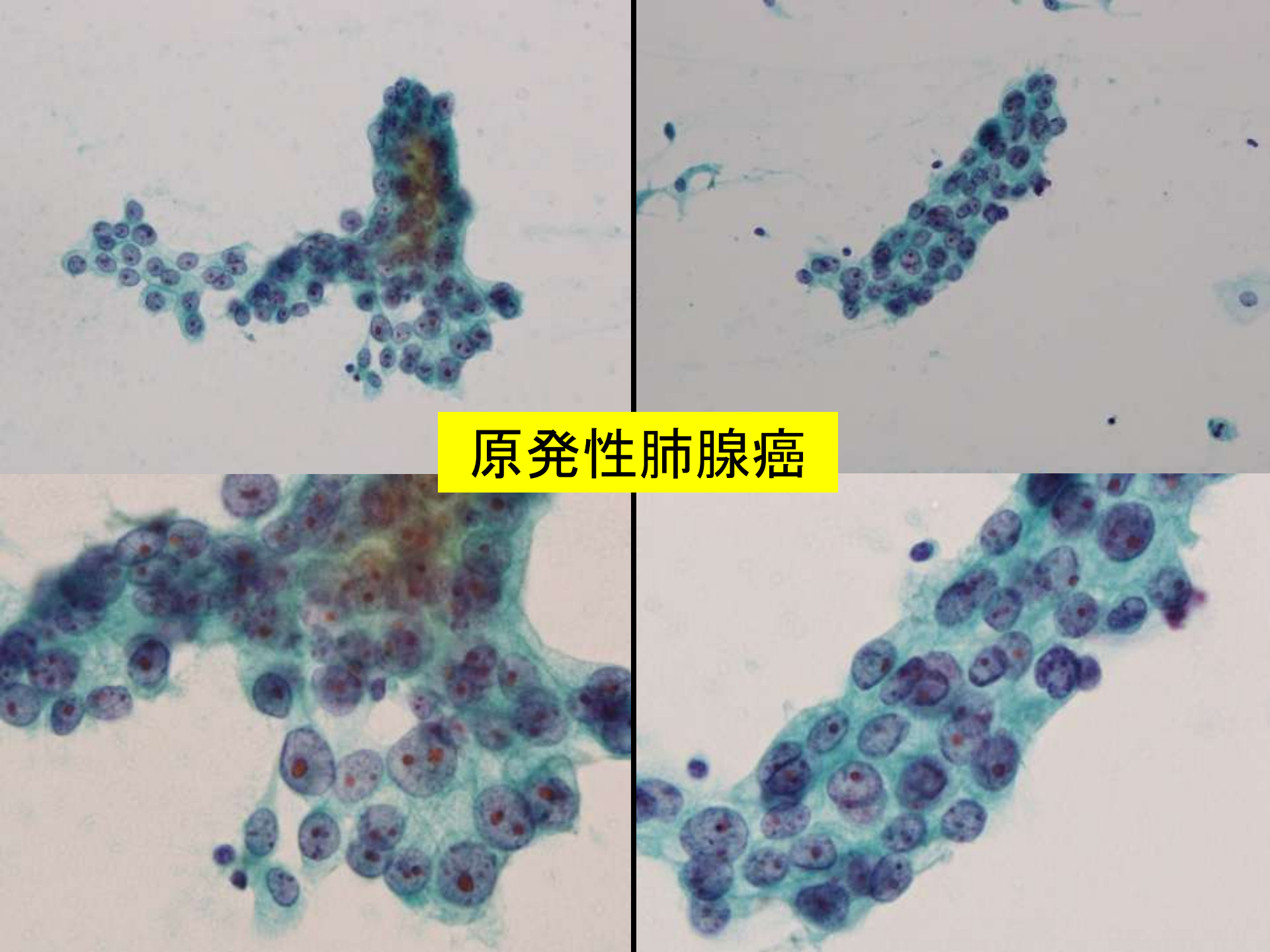
原発性肺腺癌

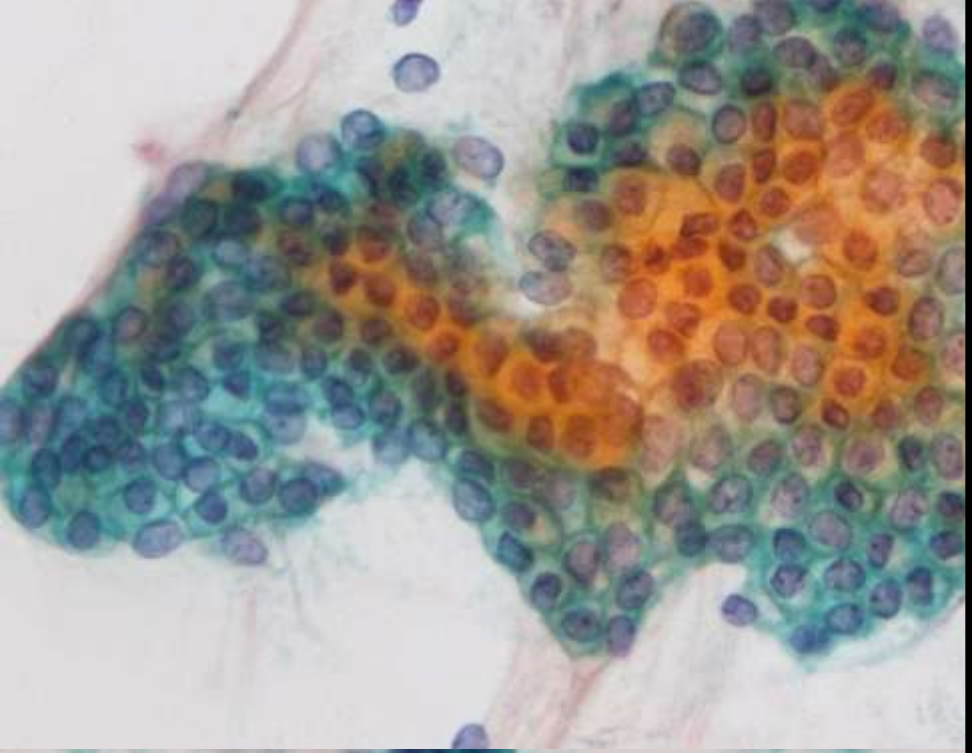

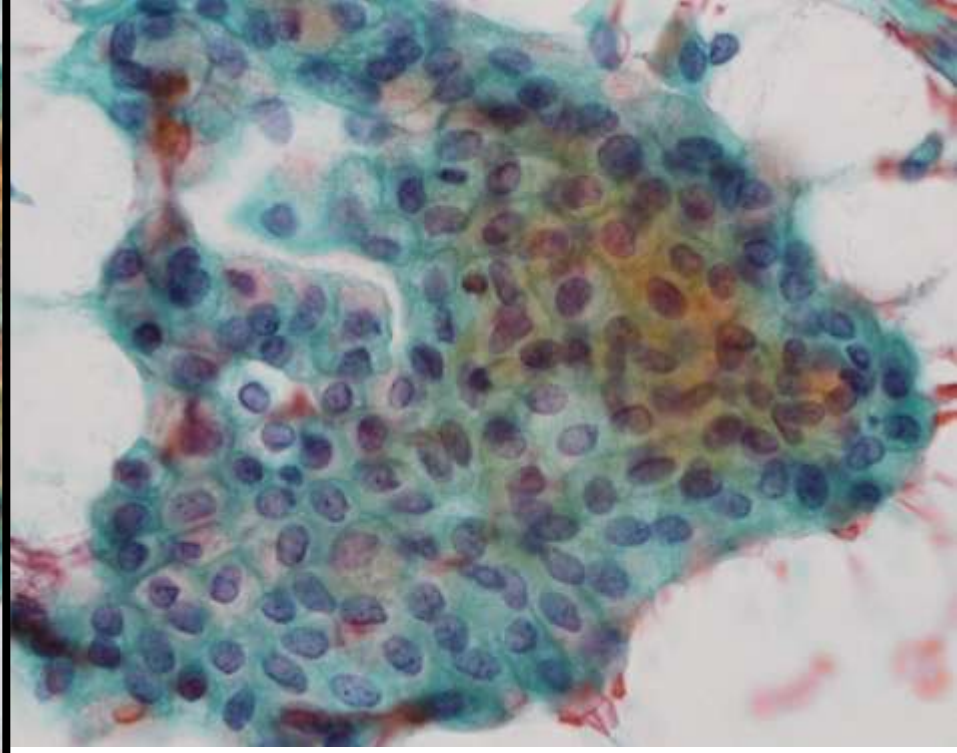

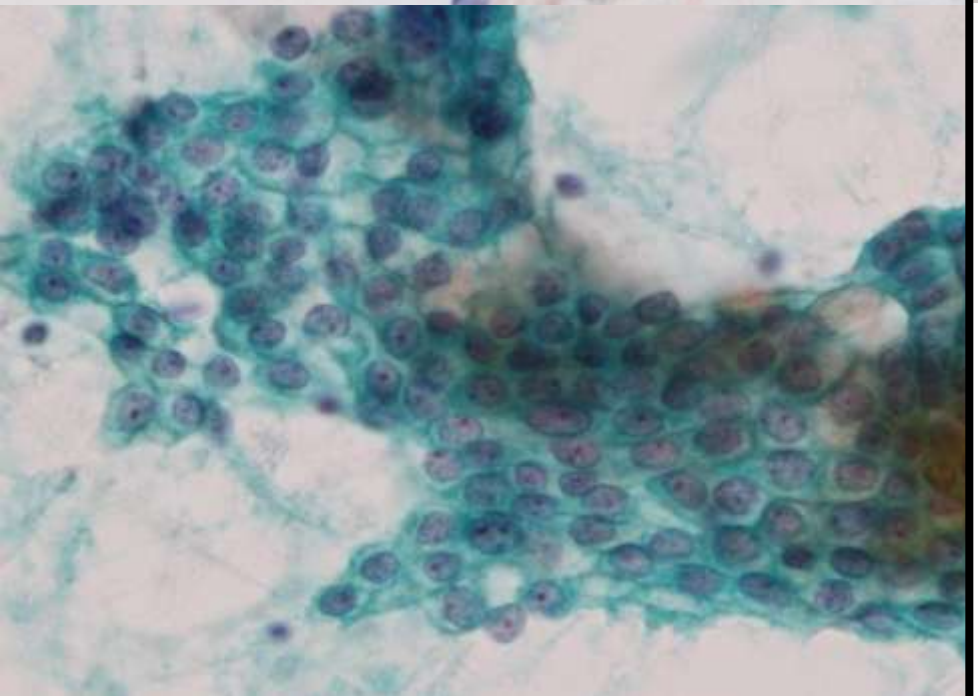

Invasive
mucinous
adenocarcinoma

**本症例**

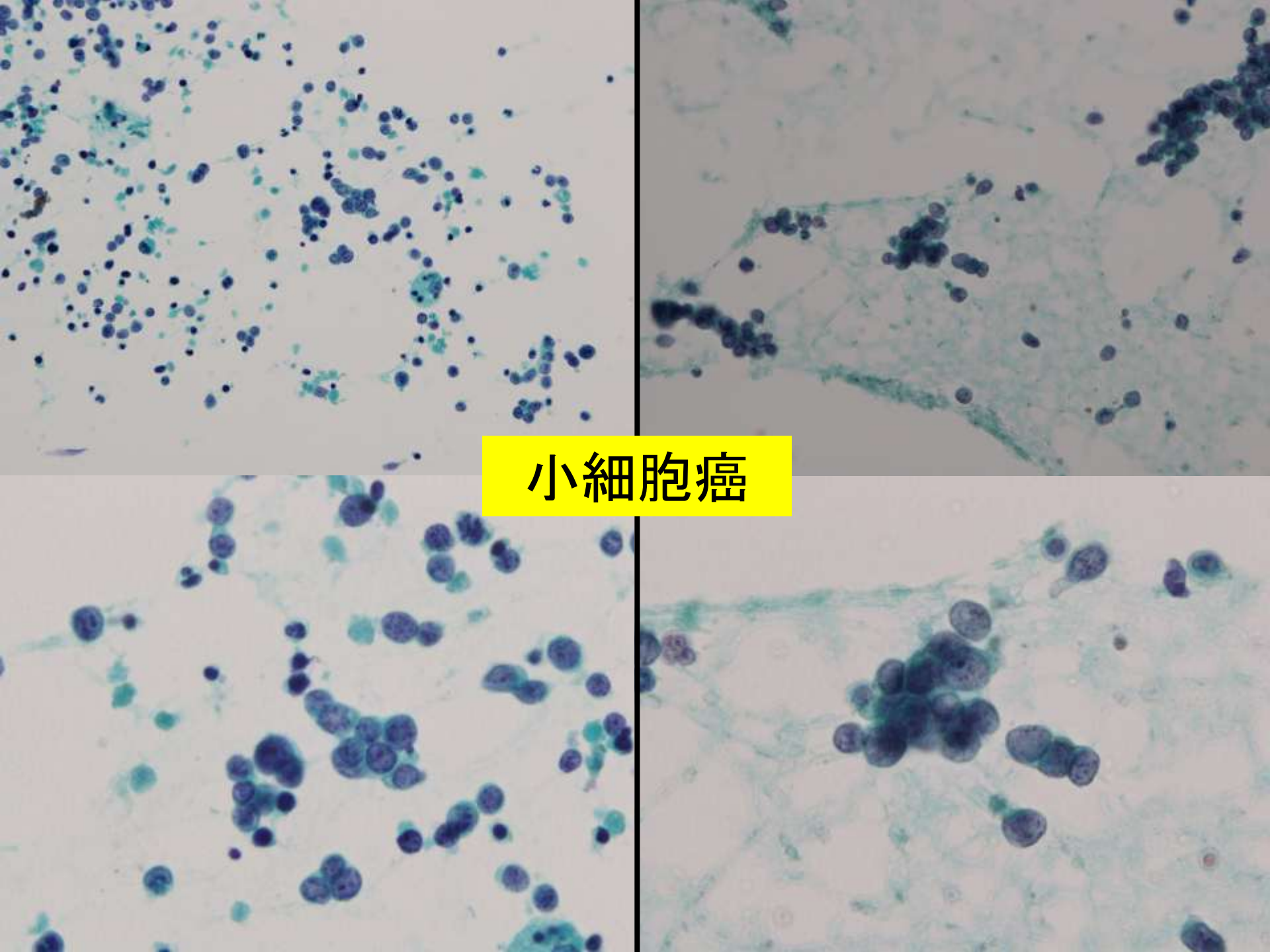
小細胞癌

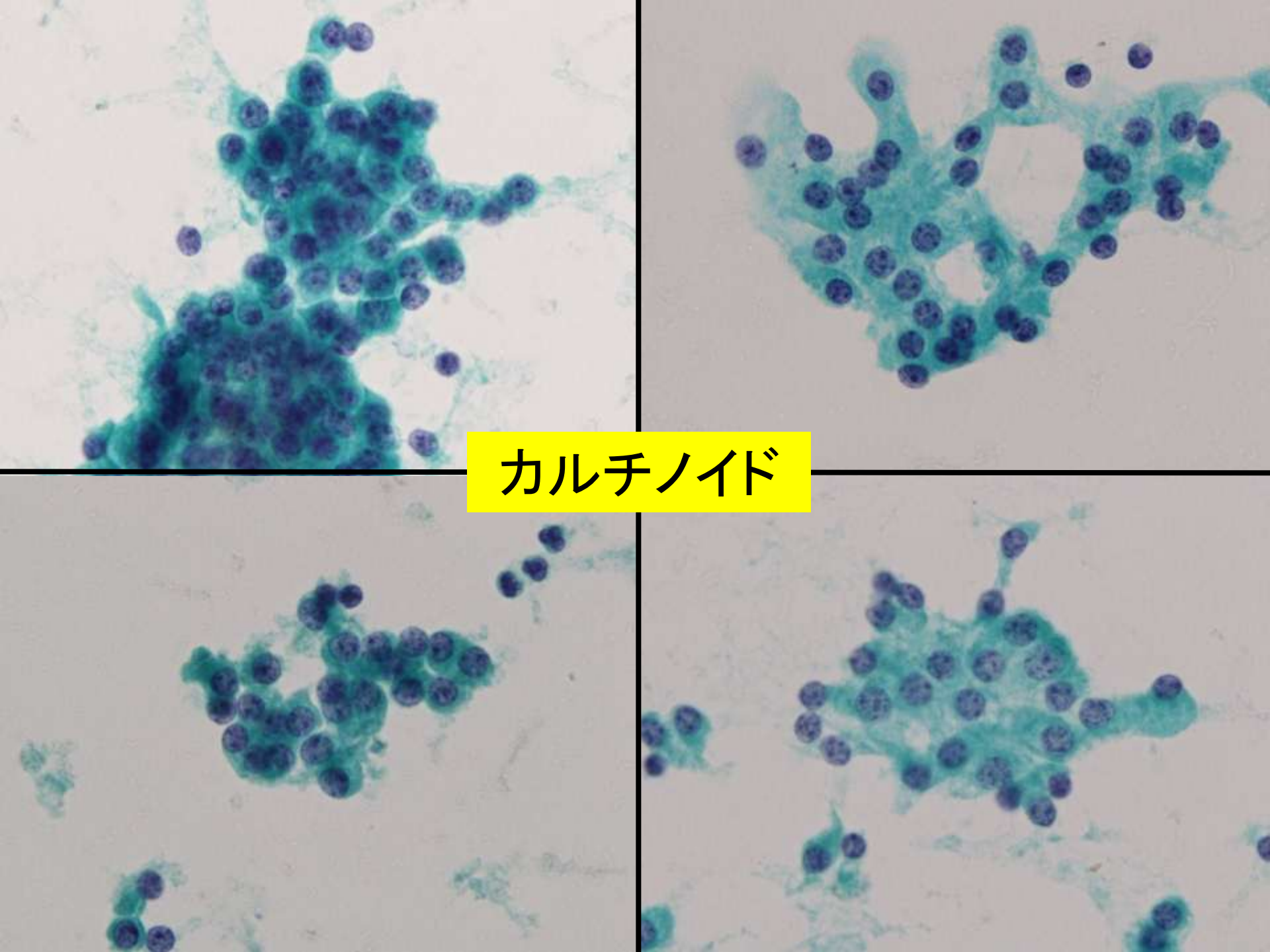
カルチノイド